

Therapeutic Effects of Ozonized Olive Oil in the Treatment of Intractable Fistula and Wound after Surgical Operation

Akiyo Matsumoto¹, Shotaro Sakurai², Nariko Shinriki³,
Shigeru Suzuki⁴ and Toshiaki Miura⁵

¹Department of Surgery, Chiba-Tokushukai Hospital,
Narashino-dai, Funabashi, 274-8503, Japan

²Department of Pharmacy, Kashiwa Municipal Hospital, Fuse, Kashiwa, 277-0825, Japan

³Tsukuba Materials Information Laboratory, Sapporo Branch, Sapporo, 062-0906, Japan

⁴Nippon Ozone Co. Ltd., Arakawa 7-4-3, Tokyo, 116-0002, Japan

⁵College of Medical Technology, Hokkaido University, Kita-ku, Sapporo, 060-0812, Japan

Abstract

20 patients at several hospitals who underwent surgical operation between August 1998 to August 2000 had ozonized olive oil applied to their intractable fistula or wounds. The ozonized olive oil treatment was fully effective in 19 of the cases. The one exception was for a case of pilonidal sinus. Ozonized olive oil was especially effective in treating intractable abdominal fistula to digestive tract after surgical operation. No adverse side effects were observed in the administration of the ozonized olive oil. It was fully effective for a discharge of pus and the formation of granulation.

Introduction

There have been many cases of intractable fistula forming after surgical operations. In Europe ozonized olive oil has been used to treat serious wounds and good results have been achieved, however it has almost never been used in clinical applications in Japan. We started to test ozonized olive oil by treating intractable wound which resulted in a cure. Since then we have applied it for many kinds of cases, e.g., intractable fistula, decubitus anal fistula, pilonidal sinus and so on. We will report good results we achieved.

Materials and Methods

The main component of ozonized olive oil was found to be triolein triozone as explained in the proceeding presentation..

Refrigerated ozonized olive oil which was obtained from Pharmoxid, Germany was brought to a viscous state at room temperature before use.

20 patients who had been treated unsuccessfully for intractable fistulas and wounds were selected. These patients had previously been treated by curettage, saline deterge, antibiotic ointment and/or drainage. Before treatment with ozonized olive oil an informed consent form was obtained.

Pus from the intractable fistulas and wounds was discharged and the ozonized oil was administered to the opening by a 1.0 or 3.0 ml syringe. After the application of the ozonized oil the fistula or wound was loosely covered by gauze. In some cases excess pus was produced so a saline detergent was used, and debridement was done in cases of necrosis. There was no administration of antibiotics either externally or orally, nor were the fistulas or wounds stuffed with gauze or drained.

Results

20 cases are shown in Table 1. The number of other treatments before the ozonized oil (saline detergent, antibiotic ointment, curettage and drainage) and the interval between treatments is shown on the center. In the right columns we show the number of treatments of the ozonized oil, dosage volume and intervals of application until the patient was cured.

There were three cases of intractable fistula after operation for inguinal hernia, including one case of intractable fistula with infected mesh (case 2), which was cured by only 5 applications of the ozonized oil.

Four cases of intractable fistula after operation for acute appendicitis with peritonitis (case 4 to 7) had difficulty in closing the opening, but after using the ozonized oil for only 3 to 10 applications they were cured. Photo.1 shows case 4 pre and post the ozonized oil treatment.

Five cases of intractable wound after operation for infected epidermal cyst were also shown. Case 11 needed 24 applications but the others soon recovered. Photo. 2 shows case 10 pre and post the ozonized oil treatment.

One case (case 13) was fistula after incision to treat an infected urachal cyst. Excretion of pus was limited but the incision wound did not easily close after the operation. However after only 3 treatments with the ozonized oil it closed.

We treated three cases of fistula after incision and drainage for infected pilonidal sinus. In case 19 the number of treatments was higher than usual but a cure was effected. Case 17 had a 3 cm diameter abscess cavity under the skin that was not cured despite many applications of the ozonized oil.

In a case of lower limb ulceration due to sunburn (case 20), a patient had a 3.0cm diameter blister. Following usual practice the blister was pricked and treated, however the abscess belaque at the bottom of the ulcer did not disappear. After application of the ozonized oil pus solidification and a drying up at the ulcer bottom started and epithelization appeared, and then the ulcer cured. This is shown in Photo. 3.

We treated three cases of fistula after incision and drainage for perianal abscess (cases 14 to 16), including one case for perivirectal abscess (case 15). We showed the cure proceedings of case 15 in Photo. 4. Abscess cavities were formed in the range of 1) ischioirectal fossa on the right, 2) internal and external obturator muscles on the left, 3) piriform muscles, 4) a part of maximum gluteal muscle. A patient had a fever over 38°C and an increase of leukocyte (15,200/mm³). After repeated incisions and drainage for perianal abscess, a decrease of excretion of pus occurred and on the 8th day from the operation the patient started to eat. However he again had a fever of 38°C and an increase in the amount of pus. We were forced

to control his condition by fasting. We found *Alpha Streptococcus* in his pus. 20 days after the operation we started to treat his fistula with the ozonized oil, then the administration of oral antibiotics became unnecessary. On the 14th day of treatment with the ozonized oil he started to have meals without a fever nor an increase in leukocyte although a small amount of pus was excreted. Photo. 4-B is a X-ray using diatorizonate sodium and shows the intractable fistula at the start for the ozonized oil treatment. Photo. 4-D shows the fistula after 18 applications of the ozonized oil, and only ramiform fistula remained in the range of 1) ischiorectal fossa on the right and the back of the rectum. In the CTs (4-E1~E3) abscess formation could not be found. On the incised part of the right side around the anus a fistula into which a sonde could only be inserted 2 cm remained and there was no excretion of pus. From then the patient became an outpatient and until now there has been no sign of recurrence.

Discussion and Conclusion

We often see intractable fistulas and wounds as a result of surgical operation. In the treatment of intractable fistulas, use of local applications of Picibanil, fiblin paste and/or medicine made from human blood coagulation factor 8, high oxygen pressure treatment and laser beam irradiation method have been reported.¹⁾⁻⁵⁾ Operation for inguinal hernia often gives rise to infected mesh (case 2) resulting in the need for a second operation. The infection is initially cured but soon gets re-infected causing a repeat hernia. In operations for acute appendicitis with diffuse peritonitis the formation of intractable fistula is often seen⁶⁾. Even in cases of relatively simple fistula observed by X-ray diatorizoate sodium treatment becomes very hard due to the difficulty in overcoming infection and the elimination of bad granulation. In cases of infected epidermal cyst, incision to eliminate pus often causes the infection to spread and consequently subcutaneous tissue is lost, increasing the difficulty in curing the wound.

We tried treating intractable fistulas and wounds with the ozonized oil, which is especially easy to apply without any special instrument. The application of the ozonized oil decreased the excretion of pus along with a corresponding increase in granulation at the rim of the wound. Then the opening reduced to a pin point or line state, and finally the excretion of pus stopped and the fistula closed. In cases of fistula with minimal excretion of pus, epithelization of the opening parts and subsequent closing were rapid. Infected urachal cysts and infected pilonidal sinuses which are not cured by antibiotics⁷⁾ usually need radical operations, however in our study they were seen to be effectively cured by the ozonized oil. Anal fistulas, which are easily formed after incision and drainage for perianal abscesses often need a radical operation, but cases 14 and 16 soon healed after application of the ozonized oil, and there has been no sign of recurrence. In case 15 a perivorectal abscess showed a rapid reduction of fistula size and a tendency to heal. Until now, after debriedment intractable fistulas and wounds were classified by their conditions and their treatment was carried out according to this classification. Wounds with large amounts of pus had saline deterge, drainage and local application of antibiotics. After the granular formation some drugs which promote the formation of granulation was used. Using the ozonized oil by itself resulted in pus solidification, an occurrence of drying, the appearance of epithelization and a decrease in the size of abscesses. The fistulas and wounds had a tendency to cure; therefore the ozonized oil itself can cure these independently. Intractable wounds that had a certain degree of granulation after debriedment of the parts of necrosis and abscess had the ozonized oil applied and this resulted in rapid epithelization and a closing of the opened wounds.

The disinfection effect of ozonized olive oil has already been reported⁸⁾. On the other hand the stimulation mechanism of the ozonized oil to the tissue (e.g., granulation and epithelization etc.) has not been clarified enough. However, in ozone treatment (e.g., autohemotherapy) ozone has been recognized to have some stimulating effects on leukocytes, e.g., induction of many cytokines was clearly confirmed by Bocci^{9,10)}. In ozone gas rinsing of ulcers caused by arterial circulation disorders (diabetes), increases of granulation tissue and epidermal epithelium were observed by Rokitansky¹¹⁾. Also in the case of ozonized olive oil some active oxygen species which are considered to be generated from the breakdown of triolein triozone will be able to react and/or stimulate the cells. About this point more study will be needed.

In conclusion we think that because of its good results with no side effects and ease of application ozonized olive oil should be used for the treatment of intractable fistulas and wounds after surgical operations.

References

- 1) Nakanishi Y, Nakajima T, Yoshimura Y et al.: Nihon Keisei-geka Gakkai Kaishi (J. Japan Soc. Plastic and Reconstructive Surgery) 17: 428-433, 1997
- 2) Hiraguchi E, Miyake Y, Sunaga M et al.: Nihon Rinsyo-geka Gakkaishi (J. Japan Surgical Assoc.) 53: 209-214, 1992
- 3) Usui A, Kubota M, Ohkita J et al.: Hinyouki-geka (Japanese J. Urological Surgery) 6 : 373-376, 1993
- 4) Kawashima M, Tamura H, Takao K et al.: Nihon Iji Shinpou (Japan Medical Journal) No.3525 : 43-45, 1991
- 5) Suguro M, Ejiri S, Sakashita T : Shohkaki Naishikyō (Endoscopia Digestiva) 9 : 411-416, 1997
- 6) Yamamoto S, Watabe T, Matsumoto Y et al.: Geka (Surgery) 57 : 149-154, 1995
- 7) Lundhus E, Gottru F : Outcome at three to five years of primary closure of perianal and pilonidal abscess. A randomised, double-blind clinical trial with a complete three-year follow up of one compared with four days' treatment with ampicillin and metronidazole. Eur. J. Surg. 159 : 555-558, 1993
- 8) Lezcano I, Nuñez N, Espino M, Gómez M : Antibacterial activity of ozonized sunflower oil, Oleozón, against *Staphylococcus aureus* and *Staphylococcus epidermidis*. Ozone Sci. Eng. 22 : 207-214, 2000
- 9) Bocci V, Paulesu L : Studies on the biological effects of ozone. 1; Induction of interferon γ on human leucocytes. Haematologica 75 : 510-515, 1990
- 10) Paulesu L, Luzzi E, Bocci V: Studies on the biological effects of ozone. 2; Induction of tumor necrosis factor (TNF- α) on human leucocytes. Lymphokine Cytokine Res. 10, 409-412, 1991
- 11) Werkmeister H : Subatmospheric O₂/O₃-treatment of therapy-resistant wounds and ulcerations. OzoNachrichten 3/4, 53-59, 1985

Table I The breakdown of 20 cases of serious post operation fistulas and wounds

Case	Age / Sex	Type of Operation	Details of Post Operative Treatments(POT)	Number of POT	Interval between POT	Number/Dosage /Interval of Application of Ozonized Olive Oil
1	63 / M	Inguinal hernia	S, A	62	days 2~3	ml / days 7 / 0.3 / 1~3
2	69 / M* ¹		S, A	10	2~3	5 / 0.2 / 1~3
3	71 / M		S, A	10	2~3	14 / 0.2 / 1~3
4	15 / F	Acute appendicitis	C, S, D, A	12	1~3	6 / 0.2 / 1~3
5	45 / M		C, S, D, A	20	1~3	10 / 0.2 / 1~3
6	59 / F		C, S, D, A	74	1~3	3 / 0.1 / 1~3
7	72 / F		C, S, D, A	20	2~3	3 / 0.2 / 2~3
8	12 / F	Infected epidermal cyst	C, S	10	1~3	3 / 0.1 / 1~3
9	37 / M		C, S	10	2~3	2 / 0.1 / 2~3
10	51 / M		S	5	2~3	4 / 0.2 / 2~3
11	72 / M		C, S, D	14	2~3	24 / 0.2 / 2~3
12	78 / F		C, S, D	15	2~3	9 / 0.1 / 2~3
13	19 / F	Incision of infected urachal cyst	S, D, A	9	2~3	3 / 0.1 / 2~3
14	49 / M	Incision and drainage for perinal abscess	S, D	26	2~3	2 / 0.3 / 2~3
15	65 / M* ²		S, D	21	0~7	18 / 1.0~2.5 / 0~7
16	70 / M		S, D	8	1~2	4 / 0.2 / 1~3
17	24 / M* ³	Incision and drainage for pilonidal sinus	C, S, D	9	2~3	13 / 0.3 / 2~3
18	24 / M		C, S, D	7	2~3	2 / 0.2 / 2~3
19	26 / M		C, S, D	8	2~3	12 / 0.2 / 2~3
20	31 / F	Debridement of lower limb ulceration	C, S	18	0~1	16 / 0.3 / 0~2

Post operative treatments: Saline deterge, S ; Antibiotic ointment, A ; Curettage, C; Drainage, D

*1: infected mesh, *2: Perivirectal abscess, *3: having a 3 cm diameter of abscess cavity

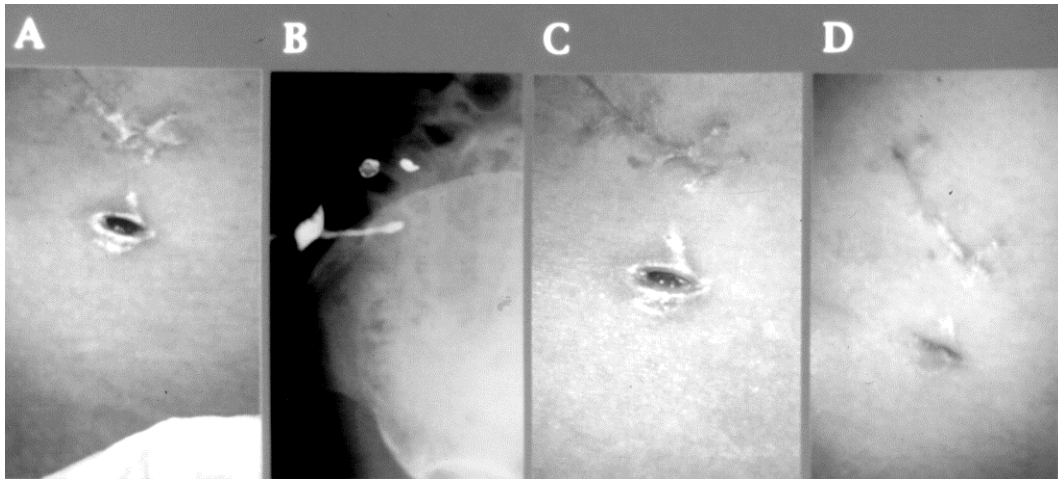


Photo. 1 Case 4: Formation of intractable fistula after operation for acute appendicitis
 A: Wound before medication of ozonized olive oil
 B: X-ray with diatorizoate sodium (X-ray) of intractable fistula
 C: Wound after one application of the ozonized oil
 D: Wound after 6 applications of the ozonized oil

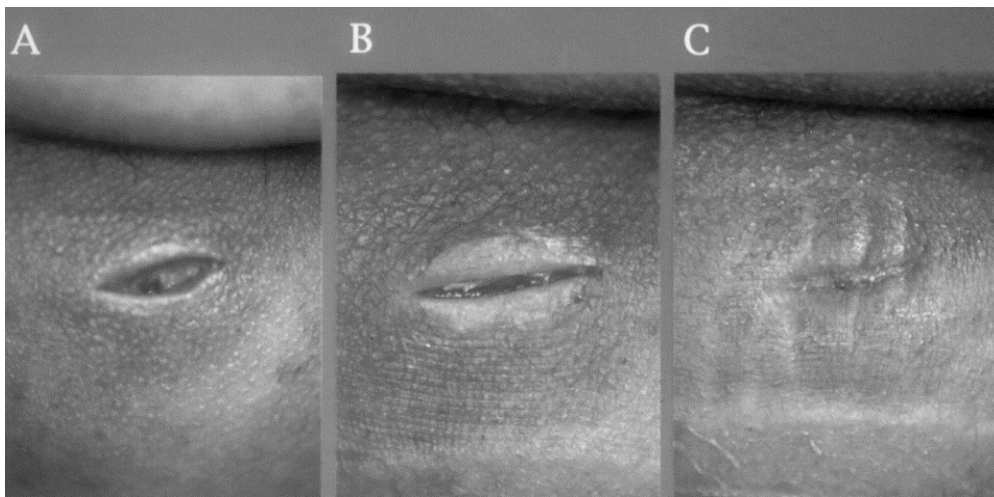


Photo. 2 Case 10: Formation of intractable fistula after operation for infected epidermal cyst
 A: Wound before medication
 B: Wound after one application of the ozonized oil
 C: Wound after 4 applications of the ozonized oil

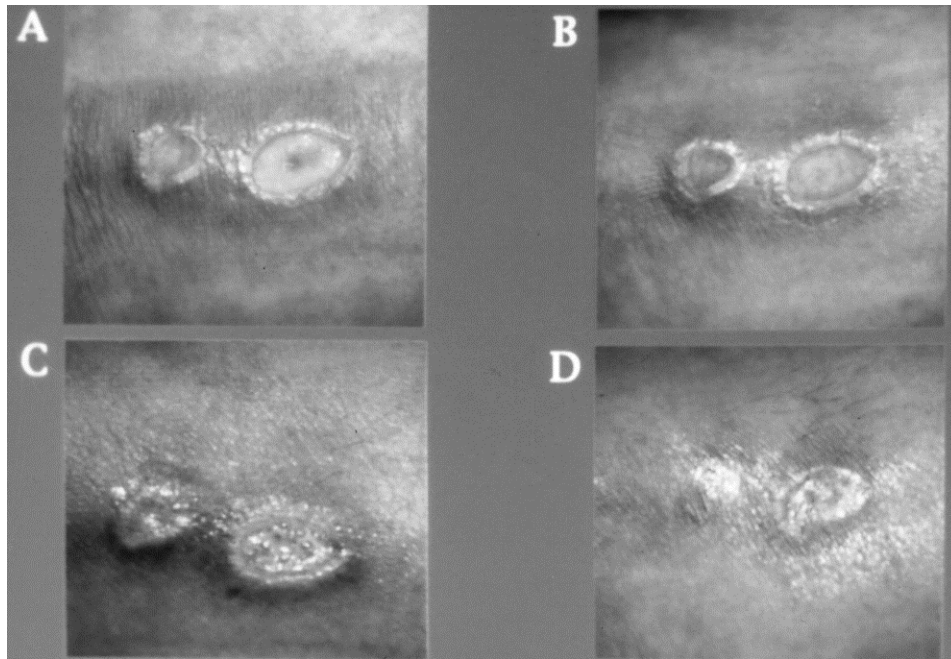


Photo. 3 Case 20: Debridement of lower limb ulceration
A: Wound before medication
B: Wound after 2 applications of the ozonized oil
C: Wound after 7 applications of the ozonized oil
D: Wound after 16 applications of the ozonized oil

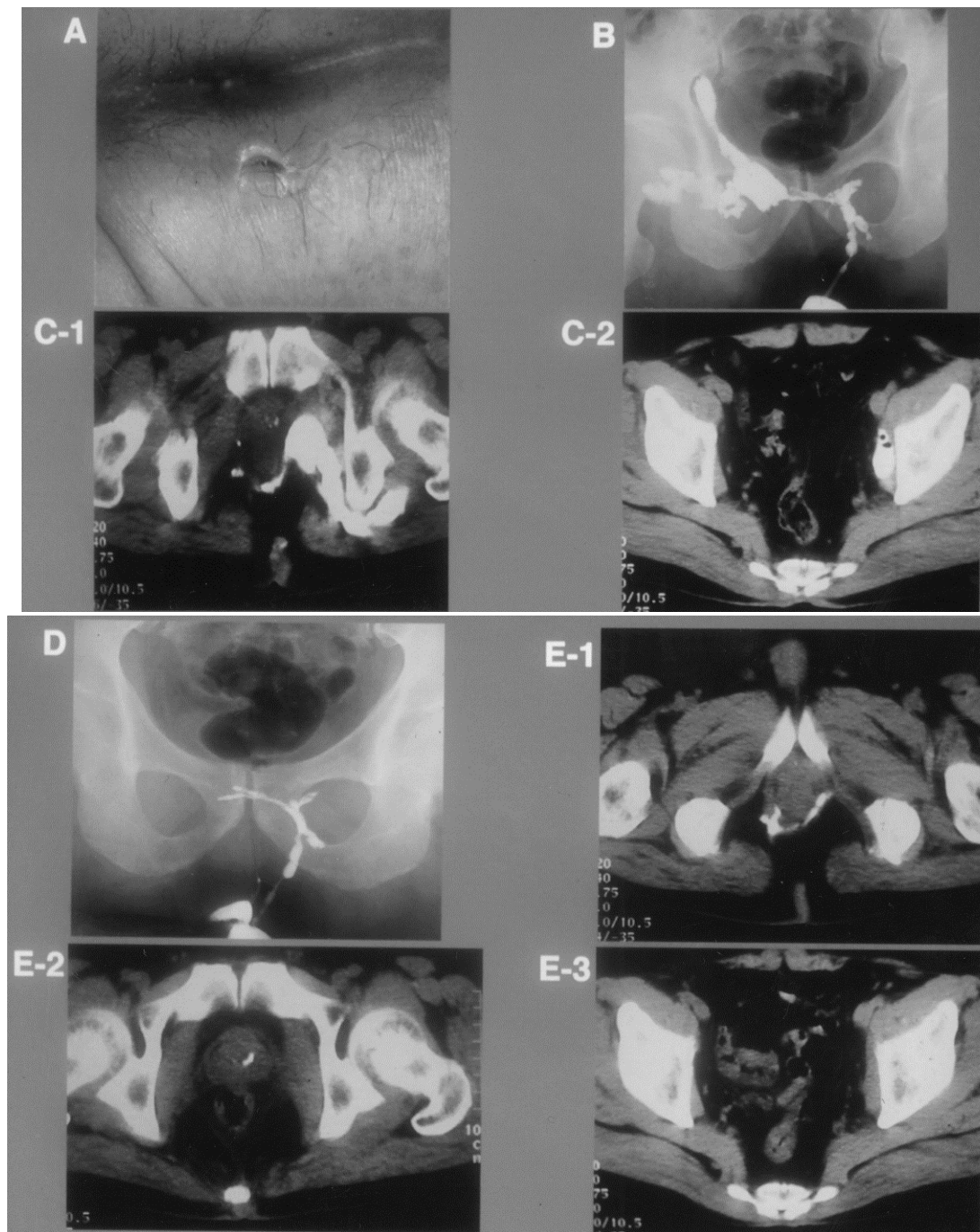


Photo. 4 Case 15: Formation of intractable fistula after incision and drainage for perianal abscess

A: Wound before medication B: X-ray of intractable fistula

C1, C2: CT with diatrizoate sodium (CT) of intractable fistula

D: X-ray of intractable fistula after 18 applications of the ozonized oil.

E1, E2, E3: CT of intractable fistula after 18 applications of the ozonized oil.

Before medication, abscess cavities were formed in the range of 1), 2), 3) and 4) in the pictures. After 18 applications, only ramiform fistula remained in the range of 1) and the back of the rectum, and abscesses in other parts were not detected by CT.

1) ischioanal fossa on the right 2) internal and external obturator muscles on the left 3) piriform muscle 4) a part of maximum gluteal muscle