

## Evaluation study of Rigenoma device with ozoile in the treatment of chronic skin lesions

Elia Ricci,<sup>1</sup> Monica Pittarello,<sup>1</sup> Francesco Giacinto<sup>2</sup>

<sup>1</sup>Casa di Cura San Luca, Servizio Ferite Difficili, Pecetto Torinese (TO); <sup>2</sup>ASP Cosenza, ambulatorio di Vulnologia, Cosenza, Italia

### ABSTRACT

Ozone has been used for medical purposes since the 1800s and for years also for the treatment of skin lesions. The properties of this molecule are multiple, including increased oxygen availability, anti-inflammatory and antiseptic. We tested the performance of a product based on Ozoile (Stable Ozonides from organic olive oil), in the treatment of chronic skin lesions. 40 patients with lesions of different aetiologies and locations in the leg or foot were recruited. The parameters analyzed were: area, infection, pain, WBP and occurrence of adverse events. The observational study included a 2-week enrollment and observation run-in and a 6-week treatment period with Ozoile. The data collected highlighted an excellent performance of the device used on all parameters. The same data, analyzed with the linear ANOVA test, showed a significance of the p on area, pain and onset of infections. The authors believe that these results confirm the hypotheses, reported in the literature, on the activity of ozone and its derivatives.

Correspondence: Elia Ricci, Casa di cura San Luca, Servizio Ferite Difficili, Strada alla Vetta 3, Pecetto Torinese (TO), Italia.  
Tel.:011544747.  
E-mail: ericcisegreteria@alice.it

Key words: Ozone; wound care; Ozoile; lesioni corniche.

Availability of data and materials: All data analyzed in this study are available in the present article.

Ethical Approval and Consent to Participate: **The INSTITUTE Ethics Committee has approved this study (CODE OF APPROVAL). This study complies with the Declaration of Helsinki of 1964, revised in 2013. The patients involved in this study have given their consent to participate.**

Consent to Publication: Patients have given their consent to the publication of data in this article.

Conflict of Interest: The authors declare no conflict of interest.

Received for posting: August 2<sup>nd</sup>, 2022.  
Revision received: November 15<sup>th</sup>, 2022.  
Accepted for publication: November 21<sup>st</sup>, 2022.

Editor's Note: The statements expressed in this article are those of the authors only and do not necessarily represent those of their affiliated organizations, nor those of the publisher, editors and reviewers. Any products rated in this article or claims made by their manufacturer are not warranted or endorsed by the publisher.

© Copyright: the Author (s), 2022  
Licensee PAGEPress, Italy  
Italian Journal of Wound Care 2022; 6(3):90  
doi:10.4081/ijwc.2022.90

This work is licensed under a Creative Commons Attribution-NonCommercial 4.0 International License (CC BY-NC 4.0).

### INTRODUCTION

Ozone is an inorganic oxidizing compound made up of three oxygen atoms. Oxygen is a fundamental element for life as we know it, and its role in wound repair can be easily guessed in an energy-intensive process such as tissue repair.<sup>1,2</sup> It is known that, in lack of oxygen, wound bed infections are more frequent.<sup>3</sup> Recently, new routes of topical oxygen administration have been codified in a document proposed by the EWMA, among these, ozonides have been evaluated capable of providing oxygen.<sup>4,5</sup>

Its first known medical application was the purification of test-tube blood in 1870.<sup>6</sup> Ozone has an ancient history of application in the treatment of skin lesions: the ozone molecule O<sub>3</sub>, with its antiseptic, antioxidant and inflammation modulating properties, is used in numerous forms, from auto-blood transfusion to rectal administration, to topical use. Over the years, ozone has been used as a treatment option for several conditions such as diabetic foot ulcers, periodontal disease, and chronic inflammation, among others.<sup>7</sup> Ozone has also been used as a disinfectant in waste water treatment and drinking water preparation due to its high antimicrobial activity.<sup>8</sup> Several studies have shown that, due to its non-specific action, ozone has an effect on bacteria, viruses, protozoa and fungi.<sup>9</sup> In this study we used a product with stable ozonides from organic olive oil for the treatment of non-healing lesions.

This kind of product now has an important supporting literature.

Wen *et al.*, in a recent review of the literature,<sup>10</sup> reported the use of topical ozonides in the treatment of post actinic, venous, digital ulcers in scleroderma, arterial ulcers and diabetic foot; in the face of the absence of evidence in the actinic lesions, an acceleration of the repair is reported in all the other types, but the data would not be significant; however, the author underlines a low level of studies. Lim *et al.*, in another review,<sup>11</sup> reported a positive effect on wound healing linked to the bactericidal, antifungal and antiviral activity of ozonated oils. Anzolin *et al.*,<sup>12</sup> in a 2020 review, underlined an antibacterial activity and an ability to debride lesions capable of modulating inflammation, stimulating cellular metabolism accelerating tissue repair. Silvia *et al.*<sup>13</sup> found an activity on the bio-film both in terms of bacterial killing and reduction of adhesion. Currò *et al.*<sup>14</sup> highlighted the anti-inflammatory and tissue regenerating action of Ozoile. Russo *et al.*<sup>15</sup> demonstrated an anti-inflammatory action of stable ozonides comparable to that of topical corticosteroids. In this study we wanted to analyze the performance of Ozoile, in topical application.

## MATERIALS AND METHODS

This was an observational study, in which each patient was a case control of himself. Patients were recruited after a 2-week run-in with gold standard treatment, followed by a 6-week treatment period using Ozoile in addition to the treatment performed in the previous phase. 40 patients were enrolled: 20 with lower limb lesions and 20 with foot lesions at two vulnology centres. All patients were informed of the protocol in question and, after signing an informed consent form, were entered.

Inclusion criteria: adults, patients with chronic skin ulcer for at least 8 weeks in the absence of necrotic eschar, self-sufficient, able to present for check-ups,

definite aetiological diagnosis, life expectancy > 6 months, not taking immunosuppressants and/or chemotherapy, not pregnant, acceptance of informed consent.

From a local point of view, a type of dressing was chosen for two weeks in accordance with the TIME guidelines,<sup>16</sup> while the underlying pathology was treated according to the gold standard of the literature.

After the run-in period, the test device in the form of a cream or spray was added to the dressing. The change of dressing took place on the basis of the exudate, daily in exuding wounds and every other day with controlled exudate. The checks took place every other week. Parameters analyzed were area (using Wound Viewer<sup>®</sup> system),<sup>17</sup> WBP (according to Falanga score),<sup>18</sup> pain (using NRS score)<sup>19</sup> and infections (using Cutting and Harding score).<sup>20</sup> The mean age of the total group was 69.3 with a range of 27–90, 70.9 in the leg group and 67.7 in the foot group. The male to female ratio was 1 to 1, the two groups were homogeneous. The mean total age of the ulcers was 10.5 months with a range of 3-29. Table 1 shows the different aetiologies divided by foot and lower limb.

## RESULTS

### Area

It is the parameter recognized by all as the most reliable in terms of repair predictability.<sup>21,22</sup>

Table 2 shows the results in terms of area evolution, while Figure 1 shows the evolution of the 2 groups in graphical form. It should be noted above all in the group of treatments how there is a constancy in the progression of the line. We evaluated the evolution of the wounds based on the area in a global sense, dividing the patients into 4 groups: resolved (total healing) 2/40, improved (reduction > 40%) 29/40, unchanged (reduction < 40%) 8/40, worsened (increased) 1/40. This leads to an overall positive result, at the end of the 6 weeks of therapy, equal to 77.5%.

**Table 1.** Etiology in the two groups.

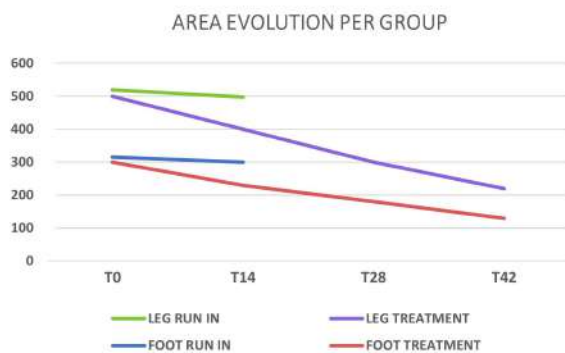
Lower limb group			Foot group		
	Num	%		Num	%
Venous	10	50	Venous	-	-
Arterial	1	5	Arterial	1	5
Mixed	7	35	Mixed	-	-
Diabetic	-	-	Diabetic	16	80
Decubitus	-	-	Decubitus	2	10
Other	2	10	Other	1	5

### Pain

The data was evaluated on 33 patients since 7 patients in the foot group, diabetics, presented a totally anesthetic neuropathy. In the run-in period, the pain reduction was 13.1%, while in the treatment period it was 35.4% at T14, 66.2% at T28 and 86.6% at T42. Note how the progression is linear here too.

### Infections

The cases of infection decreased from 21 to 16 during the run-in period (-23.8%). During the treatment period, the infections disappeared after 2 weeks, while one case re-occurred at T28 which maintained the colonization status until the final checkup.



**Figure 1.** Evolution of the area in the 2 study groups.

**Table 2.** Evolution of the area

	Run in		Treatment			
	T0	T14	T0	T14	T28	T42
Lower limb	522	497	497	412	320	257
Variation (%)		- 4,7		-17,1	- 35,6	48,2
Foot	314,8	298,3	298,3	218,8	164,8	132,9
Variation (%)		- 5,2		- 26,6	- 44,7	- 55,4
Tot. sum	836,8	795,3	795,3	630,8	484,8	389,9
Variation (%)		- 4,9		- 20,6	- 39	- 50,9

**Table 3.** Linear Anova test results ANOVA with p-values reported, significance set at < 0.5.

Data	Period	T0-T14	T15-T28	T29-T42
Total area	Run in	0.706153	-	-
	Treatment	0.077591	0.001974	0.000034
Foot area	Run in	0.806219	-	-
	Treatment	0.295636	0.097717	0.028034
Leg area	Run in	0.747705	-	-
	Treatment	0.237705	0.033281	0.001403
Pain NRS	Run in	0.168253	-	-
	Treatment	0.000121	<0.00001	<0.00001
Cutting e Harding	Run in	0.463387	-	-
	Treatment	0.004387	<0.00001	<0.00001

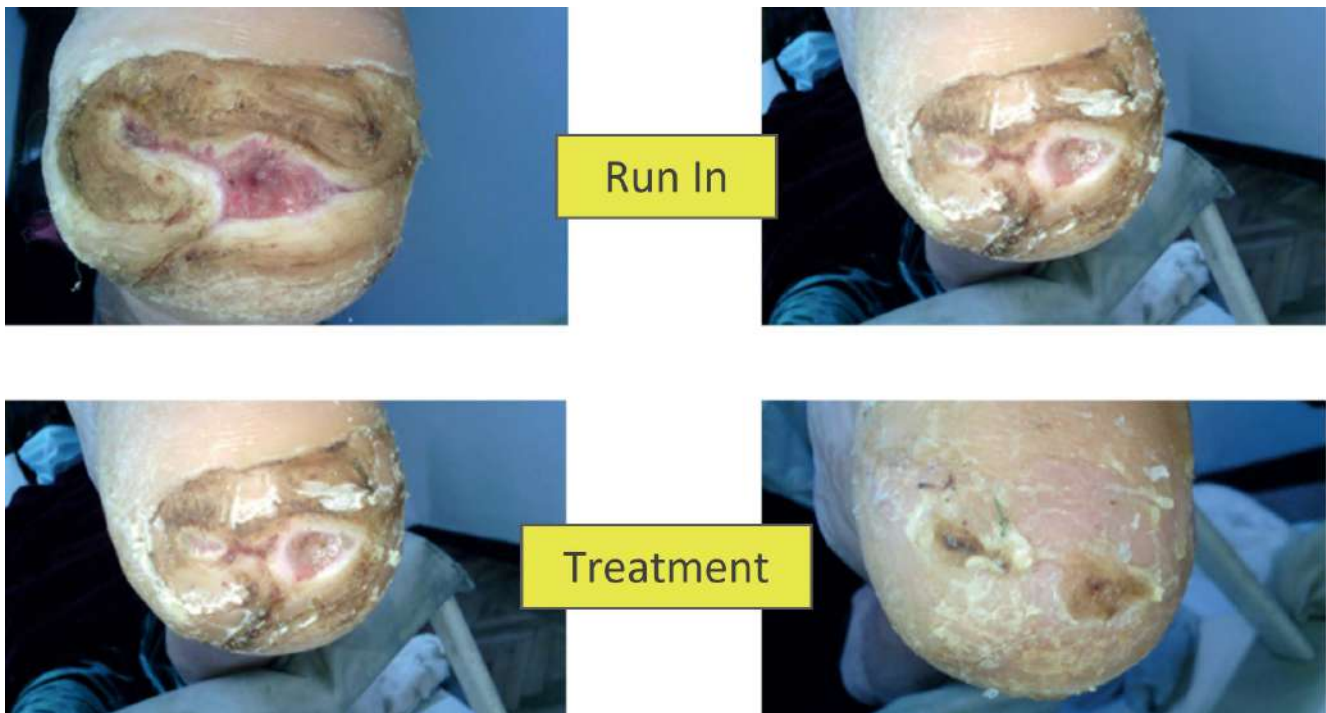
### WBP

This score does not report a numerical indicator: for the tissues, the level of cleansing is evaluated divided into 4 groups from A to D. At the end of the study, in 38 cases the wound bed was improved compared to the starting point, only 1 case has presented a deterioration, the same one that has kept in a situation of critical colonization. As for the exudate, it was totally controlled at the end of the study, in 34 cases out of 40 (90%), in 5 cases it was partially controlled (12.5%) and in one case (2.5%) outside control, but it is the same case with critical colonization.

No adverse events were noted. The only report from patients was a burning pain upon application which tended to disappear within 10-15 minutes and was apparently connected to the amount of product applied. This event occurred in 3 patients (7.5%).

### DISCUSSION

The performance of the device was quite high under all points of analysis collected. The data were analyzed using the linear ANOVA test with a significance set at  $p < 0.5$  (Table 3). The limitation of the p evaluation with ANOVA on the run-in period is due to the shortness of the observation time. The area demonstrates a level of statistical significance at 4 weeks both globally and for both locations.



**Figure 2.** Neurological foot, run in with unchanged area, resolution at 4 weeks of treatment period.

As far as pain is concerned, the fall of the same was significant from the beginning of the treatment. For infections, based on the score proposed by Cutting and Harding, maintaining a summation of the scores obtained with a value of 1 for each item, a significant reduction was highlighted from the first period of treatment.

As far as the WBP is concerned, in the chosen typology we do not have a numerical value that allows a statistical analysis. However, the result obtained is an improvement of the tissue situation equal to 95%, and a total control of the exudate in 90% of cases.

## CONCLUSIONS

This study, intended to evaluate the effectiveness of Ozoile in 4 parameters, demonstrates a valid performance of the product. The limitations of this study are mainly due to the shortness of the run-in period. The device analyzed in the absence of adverse events suggests a considerable safety of the device. It has also been hypothesized the ability to increase the availability of oxygen locally, through the division into O<sub>2</sub> and singlet oxygen. The data reported by us can probably be correlated to these points: re-epithelialization takes place in conditions of sufficient availability of O<sub>2</sub>, absence of bacterial bioburden imbalance and well-controlled inflammation; pain in the vulnological field is often related to tissue damage or infectious phenomena,

the drop in positivity on the C&H score would derive from these 2 actions. The same goes for wound bed improvement and exudate control. The low number of resolutions (Figure 2) is attributable to the short observation period of 6 weeks, against chronic lesions with an average age close to one year; however, the reduction of the area has a good level of significance equal to  $p = 0.000034$ .

## BIBLIOGRAPHY

1. Castilla DM, Liu ZJ, Velazquez O. Oxygen: Implications for Wound Healing. *Adv Wound Care (New Rochelle)* 2012;1:225–30.
2. Younis I. Role of oxygen in wound healing. *J Wound Care* 2020;29:S4-S10.
3. Gottrup F. Oxygen in wound healing and infection. *World J Surg* 2004;28:312-5.
4. Wounds UK Expert Panel Report. Consensus round table meeting: Clinical pathway for using topical oxygen therapy in practice. London: Wounds UK, 2017.
5. Gottrup F, Dissemond J, Baines C, et al. Use of oxygen therapies in wound healing. *J Wound Care* 2017;26:S1-S43.
6. Kumar T, Arora N, Puri G, et al. Efficacy of ozonized olive oil in the management of oral lesions and conditions: A clinical trial. *Contemp Clin Dent* 2016;7:51–4.
7. Borges GÁ, Elias ST, da Silva SMM, et al. In vitro evaluation of wound healing and antimicrobial potential of ozone therapy. *J. Cranio-Maxillofac Surg* 2017;45:364–70.

8. Zheng J, Su C, Zhou J, et al. Effects and mechanisms of ultraviolet, chlorination, and ozone disinfection on antibiotic resistance genes in secondary effluents of municipal wastewater treatment plants. *Chem Eng J* 2017;317:309–16.
9. Monzillo V, Lallitto F, Russo A, et al. Ozonized Gel Against Four Candida Species: A Pilot Study and clinicala perspective. *Materials* 2020;13:1731.
10. Wen Q, Liu D, Wang X, et al. A systematic review of ozone therapy for treating chronically refractory wounds and ulcers. *Int Wound J* 2022;19:853-70.
11. Lim Y, Lee H, Woodby B, Valacchi G. Ozonated Oils and Cutaneous Wound Healing. *Curr Pharm Des* 2019;25:2264-78.
12. Anzolin AP, Lucca da Silveira-Kaross L, Dallazem Bertol D. Ozonated oil in wound healing: what has already been proven? *Med Gas Res* 2020;10:54-9.
13. Silvia V, Peirone C, Amaral JS, Capita R. High efficacy of ozonated oils on the removal of biofilms produced by methicillin-resistant staphylococcus aureus (MRSA) from infected diabetic foot ulcers. *Molecules* 2020;25:3601.
14. Currò M, Russo T, Ferlazzo N, et al. Anti-inflammatory and tissue regenerative effects of topical treatment with ozonated olive oil/vitamin e acetate in balanitis xerotica obliterans. *Molecules* 2018;23:645.
15. Russo T, Currò M, Ferlazzo N, et al. Stable ozonides with vitamin E acetate versus corticosteroid in the treatment of lichen sclerosus in foreskin: evaluation of effects on inflammation. *Urol Int* 2019;16.
16. Harries RL, Bosanquet DC, Harding KG. Wound bed preparation: TIME for an update. *Int Wound J* 2016;13:8–14.
17. Zoppo G, Marrone F, Pittarello M, et al. AI technology for remote clinical assessment and monitoring. *J Wound Care* 2020;29:692-706.
18. Falanga V. Classification for wound bed preparation and stimulation of chronic wounds. *Wound Repair Regen* 2000;8:347-52
19. Breivick H, Borchgrevink PC, Allen SM, et al. Assesment of pain. *B J Anaesth* 2008;101:17-24.
20. Cutting KF, Harding KG. Criteria for identifying wound infection. *J Wound Care* 1994;3:198-201.
21. Flanagan M. Wound measurement: can it help us to monitor progression to healing?. *J Wound Care* 2003;12:189–94.
22. Kantor J, Margolis DJ. Efficacy and prognostic value of simple wound measurements. *Arch Dermatol* 1998;134:1571–4.