

Debridement and healing time reduction for chronic venous ulcers in patients treated with topical application of Ozoile and compression therapy

Authors:

Rolando Tasinato, Gaia Zagolin,
Max Dei Negri, Gaia Degli Angeli
and Myriam Maritan

This paper reports a randomised clinical trial of 81 patients with phlebostatic ulcers of the lower limbs who underwent treatment with topical application of Ozoile. The results were compared with a control group which did not receive the treatment. The trial lasted 9 months overall. Over this period of time, patients treated with Ozoile showed a statistically meaningful reduction ($P>0.007$) of mean re-epithelialisation time compared to the control group. Biopsies of the floor and margins of the ulcers treated topically with Ozoile were performed and analysed histologically and demonstrated that topical ozone application stimulates fibroblast proliferation and neoangiogenesis. Such mechanisms, combined with debridement and compression therapy, make for an efficient treatment strategy for phlebostatic ulcers, providing treated patients with a reduction of healing time and better quality of life.

During the latest years, several experiences regarding topical ozone application for the treatment of chronic cutaneous lesions were reported in scientific literature. Ozone's antiseptic properties have been exploited to reduce bacterial and microbial load mostly in bacteria-infected wounds and at the floor level of chronic cutaneous ulcers, both in acute and chronic phases (Fitzpatrick et al, 2018).

In dermatology, ozone is used for the treatment of skin infections, especially those caused by pathogens that have developed resistance to conventional therapeutic approaches with antibiotics or antimycotic medications (Zeng and Lu, 2018; Lim et al, 2019).

In addition, ozone stimulates regenerative processes that facilitate re-epithelialisation of chronic skin ulcers. When bound to oil-rich substances, it remains firmly in contact with tissues, releasing molecular oxygen which can then exert its bacteriostatic and antiseptic activity on bacteria, and anaerobes especially (Borges et al, 2017).

It was demonstrated that the presence of ozone in cultured tissues induces the production of endothelial growth factors, such as VEGF (Vascular Endothelial Growth Factor), that lead to the formation of new vessels, which improve blood

flow to the floor and margins of the lesions.

In vitro, ozone was also shown to induce fibroblast migration towards the floor of the ulcer and facilitate neoangiogenesis.

Different mixing techniques suggested in the past, although efficient, were often unable to supply stable preparations with progressive and controlled ozone release. Topical application of ozone-releasing preparations caught the interest of many teams working with acute and chronic skin lesions in the field of wound care (Kim et al, 2009; Krkl et al, 2016).

Recently, we evaluated the use of Ozoile, a biological inducer obtained from a patented mixing process in which ozone is bound to oleic acid forming stable ozonides. The formula we used for the study is patented, produced and distributed in Italy by Erbagil® s.r.l.

Materials and methods

Between August 2021 and May 2022, a total of 81 patients were evaluated. These patients (43 men and 38 women aged 64.7 years on average, in a 49–83-year range) presented with chronic skin ulcers of the lower limbs of vascular origin. The ulcers had been active for at least 6 weeks and originated from venous vessels. The venous aetiology of the

Rolando Tasinato, Gaia Zagolin, Max Dei Negri and Gaia Degli Angeli; all at General and Vascular Surgery Department, Mirano General Hospital, Venice, Italy;
Myriam Maritan, Department of Emergency, Mirano General Hospital, Venice, Italy

lesions was documented in each case by clinical examination, Color-Doppler imaging and reflection photoplethysmography.

Inclusion criteria comprised: being over 18 years of age, suffering from severe chronic venous insufficiency graded C6 on the CEAP classification and absence of other relevant comorbidities (such as NYHA class III or IV chronic cardiopathy, insulin-dependent diabetes mellitus, obesity with a BMI >40, active neoplasm, COPD, concurrent treatment with corticosteroid or immunosuppressor drugs, legs arteriopathy with an ABI index <0.7).

Patients were subsequently randomised into two groups. Patients in group A (41 patients) were treated following the TIME protocol according to EWMA's (European Wound Management Association) directions.

Besides ulcer debridement, patients in this group underwent both compression therapy and application of Ozoile spray and Ozoile cream. None of the patients was previously treated with other protocols. The cleansing of the bottom of the ulcer was carried out with a physiological solution applied for 3 minutes.

Ozoile spray was applied to the floor of the ulcer, while the Ozoile-containing emulsion was applied to the perilesional skin. Group B patients were likewise treated with debridement according to the TIME model and cleansing with repeated washes of saline solution, followed by application of sodium hypochlorite 0.05% solution for about 3 minutes and compression therapy, but they did not undergo application of the Ozoile products.

Medications were performed every 3 days on average. Short-stretch elastic cohesive bandages were applied, using the multi-layer technique, starting from the metatarsal region and proceeding upwards towards the knee, excluding the latter. After being applied the bandage, each patient was asked to walk, being given no functional limitation to his or her motor activity.

The two groups of patients were treated by the same team, composed of two physicians and three nurses. After the randomisation medication was administered, elastic bandages were applied using the same technique, with no differences between groups A and B.

Patient randomisation and data collection were performed independently through the use of an FH VMA Electronic Case Report Form (eCRF). All patients consented to the treatment and the two groups proved to be homogeneous in anthropological features and biographical data at statistical analysis.

The patients randomised in the study were subjected to two weekly evaluations on average,

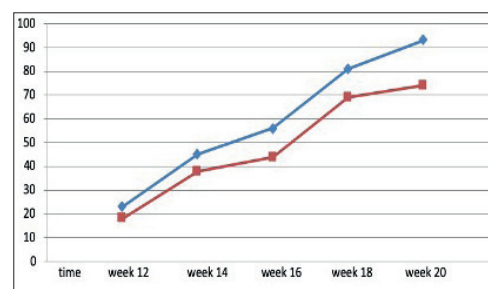


Figure 2. Diagram analysing the trend of the percentage of chronic venous ulcers that healed comparing group A and group B: patients in group A treated with Ozoile and patients in group B treated with standard treatment (blue line is group A, red line is group B).

every 3–4 days, to check on the status of their lesion's scarring process and renew medication and bandages. Every week, ulcer size, depth and exudate entity were measured for each patient, and the acquired data set was reported in the medical records. The results of these periodic measurements were then inserted into an electronic database accompanied by photographic evidence.

The aim of the study was to investigate the presence of statistically significant differences in ulcer healing rates among the two groups.

Results

Patients were observed for a period of 10 months overall, during which 2 patients abandoned the study because of intercurrent SARS-CoV-2 infection. Final data refer to 79 patients (40 from group A, 39 from group B) who successfully concluded the therapeutic protocol showing healing of the ulcer. The intention to treat (ITT) analysis was statistically conducted on a total of 81 patients treated overall.

The trend for re-epithelialisation time observed in the two groups is reported in *Figure 1*.

Phlebostatic ulcer healing rate was found to be higher in group A patients (patients treated with Ozoile) than in group B patients (control group). Independent statistical analysis of the data set shows that at 12 weeks past T0 mean healing time was reduced by 24.2%, at 16 weeks from T0 it was reduced by 26.3% and at 18 weeks by 15.1%. In comparison to the control group, patients who received both compression therapy and Ozoile topical application experienced a mean reduction of approximately 23.8%. Mild atopic reaction to the Ozoile-containing cream was observed in group A, but treatment suspension was not necessary.

In addition, group A patients relied on less analgesic therapy than patients in group B, and exudate control was more efficient. This aspect led the subjects to a faster return to their working

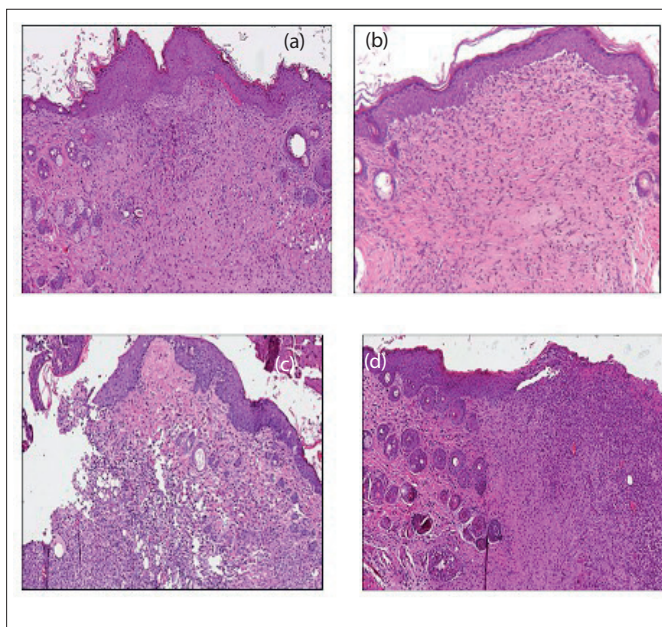


Figure 2. Optical microscopy images obtained from incisional biopsies of the perilesional skin of a patient after 4 applications of Ozoile Spray to the floor of the lesion and Ozoile cream to the perilesional skin. The biopsies were performed 21 days after application of the medication (Figure 2a and Figure 2b to Figure 2c and Figure 2d): after 3 weeks, the epithelium appears more structured and stratified and several newly-formed small vessels appear in the connective tissue under the derma, indicating the presence of active neovascularization.

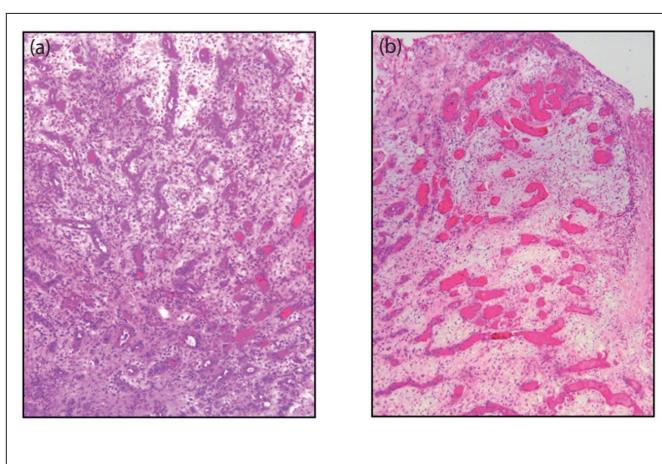


Figure 2. Histological sample with hematoxylin and eosin stain. The biopsy was obtained from the floor of a chronic ulcerative skin lesion of phlebotatic origin. The patient (male, 63 years old) was treated with sequential applications of Ozoile Spray and Ozoile cream to the perilesional skin. Observation at T0 is reported in (a): besides tissue dismantlement, notable bacterial contamination can be seen; (b) representing a biopsy obtained after 4 weeks of treatment, there appear areas of granulation tissue and neovascularization.

activity and gave both patients and caregivers a better perception of their own quality of life.

Discussion

In the first phase, Ozoile application to the floor of the ulcers shows faster debridement of the treated lesions. Ozone release into the cellular medium promotes cleansing of the floor from bacterial and fungal populations in the biofilm, both by stimulating autolytic debridement and by acting as an antiseptic (Xiao et al, 2017; Silva et al, 2020). In this study, this action characterises the first 2–3 weeks of treatment [Figure 2].

Some patients had histological examinations, which included a 5mm punch biopsy of the lesion's floor and margins. Optical microscopy was then used to demonstrate the efficacy of Ozoile-containing preparations in promoting reparative processes, mostly granulation tissue formation and neovascularization accompanying the process of re-epithelialisation (Valacchi et al, 2013; Izardi et al, 2019).

Histological examination reveals that when applied to the ulcer floor and to perilesional skin, Ozoile is capable of stimulating the activation of cellular lines responsible for tissue repair in chronic ulcerative lesions (Monzillo et al, 2020).

Moreover, qualitative and quantitative examinations of the cell populations revealed through microscopy that progressive application of the Ozoile-based preparation has anti-inflammatory effect, followed by a remarkable reduction in the number of inflammatory response-related cells. This effect can be observed starting from the third week of application on average and lasts up until the scarring process is complete (Solovăstru et al, 2015; Krkl et al, 2016; Zeng and Lu, 2018; Xiao et al, 2021).

By stimulating repair processes, Ozoile application is responsible for a temporary flareup of the lesion. This temporary transformation of the lesion from chronic to acute paves the way for the initialisation of the re-epithelialisation process carried out mainly through fibroblast migration and subsequent formation of newly-vascularised epithelium (Xiao et al, 2017; Pietrocola et al, 2018; Ugazio et al, 2020; Cho et al, 2021; Tualzik et al, 2021).

Stimulation of the repair processes is also noticeable in the histological examinations of patients in group B, who were not treated with Ozoile, but cell populations involved in scar formation and neovascularization appear later and less remarkably than in group A.

Conclusions

Debridement and compression therapy are regarded

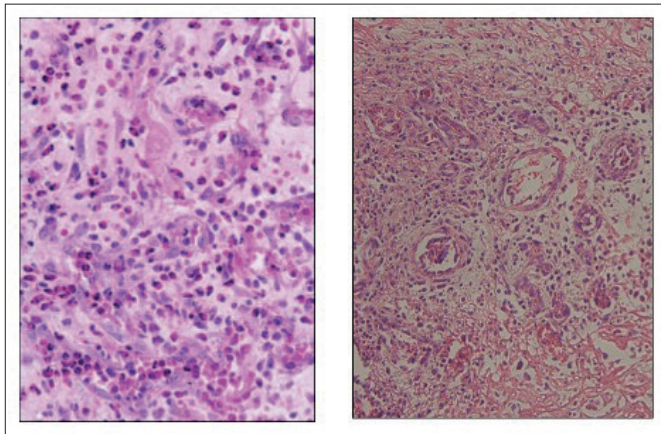


Figure 3. Higher magnification detail. Active fibroblasts proliferation and neovascularization can be observed.

as the gold standard treatment for chronic venous ulcers (Prządka et al, 2022; Zerillo et al, 2022). The duration of the treatment is influenced by the quality of the medication. In our experience, the use of ozonised oil (Ozoile)-containing preparations offers remarkable advantages by means of increasing ulcer re-epithelialisation. In addition, Ozoile stimulates epithelial regenerative processes (Cipriani et al, 2021; Wen et al, 2022) and reduces bacterial load at the floor of the ulcer. Despite our encouraging results, additional studies with larger patient populations will be required to confirm the protocol's validity over time.

WINT

References

- Borges GÁ, Elias ST, da Silva SM et al (2017) In vitro evaluation of wound healing and antimicrobial potential of ozone therapy. *Craniomaxillofac Surg* 45(3): 364–70. doi: 10.1016/j.jcms.2017.01.005.
- Cho KH, Kang DJ, Nam HS et al (2021) Ozonated Sunflower Oil Exerted Protective Effect for Embryo and Cell Survival via Potent Reduction Power and Antioxidant Activity in HDL with Strong Antimicrobial Activity. *Antioxidants (Basel)* 10(11): 1651. doi: 10.3390/antiox10111651
- Cipriani F, Lucattelli E, De Rosa M, Di Lonardo A (2021) Effectiveness of reactive oxygen species in an oil-based medication for healing burn wounds: a case series. *Ann Burns Fire Disasters* 34(2): 170–4
- Izadi M, Kheirjou R, Mohammadpour R et al (2019) Efficacy of comprehensive ozone therapy in diabetic foot ulcer healing. *Diabetes Metab Syndr* 13(1): 822–5. doi: 10.1016/j.dsx.2018.11.060.
- Fitzpatrick E, Holland OJ, Vanderlelie JJ (2018) Ozone therapy for the treatment of chronic wounds: A systematic review. *Int Wound J* 15(4): 633–44. doi: 10.1111/iwj.12907.
- Kim HS, Noh SU, Han YW et al (2009) Therapeutic effects of topical application of ozone on acute cutaneous wound healing. *J Korean Med Sci* 24(3):3 68–74. doi: 10.3346/jkms.2009.24.3.368.
- Krkl C, Yiğit MV, Özercan İH et al (2016) The effect of ozonated olive oil on neovascularization in an experimental skin flap model. *Adv Skin Wound Care* 29(7): 322–7. doi: 10.1097/01.ASW.0000484172.04260.46.
- Lim Y, Lee H, Woodby B, Valacchi G (2019) Ozonated Oils and Cutaneous Wound Healing. *Curr Pharm Des* 25(20): 2264–78. doi: 10.2174/1381612825666190702100504.
- Prządka P, Kuberka M, Skrzypczak P, Kielbowicz Z (2022) Healing of a large skin defect in a dog with concurrent ozonated olive oil application. *J Small Anim Pract* 63(6): 492. doi: 10.1111/jsap.13477. Epub 2022 Jan 18
- Valacchi G, Zanardi I, Lim Y et al (2013) Ozonated oils as functional dermatological matrices: effects on the wound healing process using SKH1 mice. *Int J Pharm* 458(1): 65–73. doi: 10.1016
- Monzillo V, Lallitto F, Russo A et al (2020) Ozonized el against four candida species: a pilot study and clinical perspectives. *Materials (Basel)* 13(7): 1731. doi: 10.3390/m
- Krkl C, Yiğit MV, Özercan İH et al (2016) The effect of ozonated olive oil on neovascularization in an experimental skin flap model. *Adv Skin Wound Care* 29(7): 322–7. doi: 10.1097/01.ASW.0000484172.04260.
- Pietrocola G, Ceci M, Preda F et al (2018) Evaluation of the antibacterial activity of a new ozonated olive oil against oral and periodontal pathogens. *J Clin Exp Dent* 10(11): e1103–e1108. doi: 10.4317/jced.54929. eCollection
- Silva V, Peirone C, Amaral JS et al (2020) High efficacy of ozonated oils on the removal of biofilms produced by methicillin-resistant staphylococcus aureus (MRSA) from infected diabetic foot ulcers. *Molecules* 25(16): 3601. doi: 10.3390
- Solovăstru LG, Stîncanu A, De Ascentii A et al (2015) Randomized, controlled study of innovative spray formulation containing ozonated oil and α-bisabolol in the topical treatment of chronic venous leg ulcers. *Adv Skin Wound Care* 28(9): 406–9. doi: 10.1097/01.ASW.0000470155.29821.ed
- Tualzik T, Chopra R, Gupta SJ et al (2021) Effects of ozonated olive oil and photobiomodulation using diode laser on gingival depigmented wound: A randomized clinical study. *Indian Soc Periodontol* 25(5): 422–6. doi: 10.4103/jisp.jisp_655_20. Epub 2021 Aug 30
- Ugazio E, Tullio V, Binello A et al (2020) Ozonated oils as antimicrobial systems in topical applications. Their characterization, current applications, and advances in improved delivery techniques. *Molecules* 25(2): 334. doi: 10.3390
- Wen Q, Liu D, Wang X et al (2022) A systematic review of ozone therapy for treating chronically refractory wounds and ulcers. *Int Wound J* 19(4): 853–70. doi: 10.1111/iwj.13687.
- Xiao W, Tang H, Wu M et al (2017) Ozone oil promotes wound healing by increasing the migration of fibroblasts via PI3K/Akt/mTOR signaling pathway. *Biosci Rep* 37(6): BSR20170658. doi: 10.1042/BSR20170658.
- Xiao W, Tang H, Wu M et al (2017) Ozone oil promotes wound healing by increasing the migration of fibroblasts via PI3K/Akt/mTOR signaling pathway. *Biosci Rep* 37(6): BSR20170658. doi: 10.1042.
- Xiao WR, Wu M, Bi XR (2021) Ozone oil promotes wound healing via increasing miR-21-5p-mediated inhibition of RASA1. *Wound Repair Regen* 29(3): 406–16. doi: 10.1111/wrr.12907.
- Zeng J, Lu J (2018) Mechanisms of action involved in ozone-therapy in skin diseases. *Int Immunopharmacol* 56: 235–41. doi: 10.1016/j.intimp.2018.01.040.
- Zerillo L, Polvere I, Varricchio R et al (2022) Antibiofilm and repair activity of ozonated oil in liposome. *Microb Biotechnol* 15(5): 1422–33. doi: 10.1111/1751-7915.13949.